

Epidermal Hyperplasia without dysplasia

Patient:

35-year-old white female

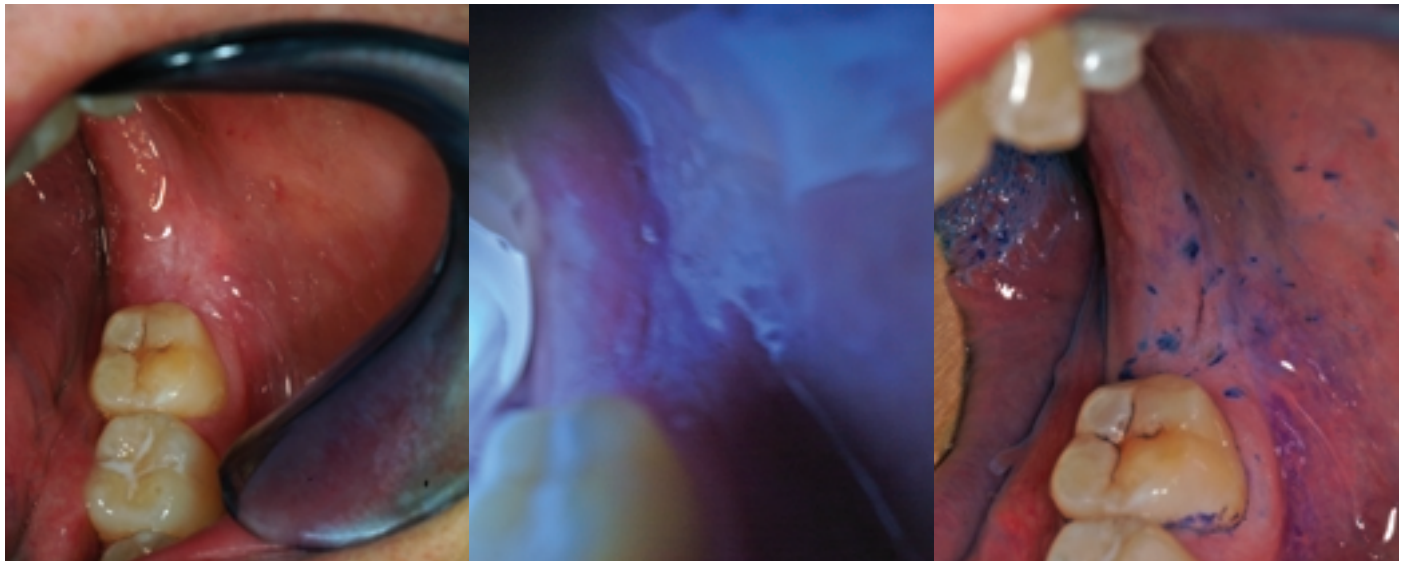
Situation:

After prophylaxis patient consented to Vizilite exam. Lesion was not visible under Vizilite light. Lesion was then stained with TBlue⁶³⁰, the lesion absorbed the stain.

Treatment/Diagnosis:

Patient was found to have Epidermal Hyperplasia without dysplasia and was referred to oral surgeon for removal and treatment. Patient was treated successfully and fully recovered with no ill effects.

Enhanced standard of care, now Vizilite Plus with TBlue⁶³⁰ make screening more comprehensive. Only Vizilite's advanced light technology makes it easier to see barely discernable lesions.



APPEARANCE OF LESION IN INCANDESCENT LIGHT

UNDER VIZILITE ILLUMINATION

MARKED WITH TBLUE⁶³⁰



Better screening saves lives